

Auditory-Visual Synesthesia

Sound-Induced Photisms

Lawrence Jacobs, MD; Alice Karpik, MD; Diana Bozian; Svend Gøthgen, MD

• Nine patients with visual loss due to lesions of the optic nerve or chiasm experienced photisms induced by sound. Descriptions of these varied from simple flashes of white light to complicated colorful hallucinations likened to a flame, a petal of oscillating lines, a kaleidoscope, or an ameba; they always appeared within a defective portion of the visual field as demonstrated by perimetry. The provoking sounds were usually those of normal daily life, ranged from soft to loud, and always seemed to be heard by the ear ipsilateral to the eye in which the photism was seen. Sound-induced photisms occurred under circumstances that would promote a startle reaction to sound, and each patient was startled when the photisms occurred. Visual evoked responses demonstrated partial deafferentation of the eye in which photisms were seen in seven patients tested. The phenomenon may occur when the patient with a partially deafferent anterior visual pathway is startled by sound.

(Arch Neurol 1981;38:211-216)

Accepted for publication July 5, 1980.

From the Harry M. Dent Neurologic Institute, Millard Fillmore Hospital, Buffalo, NY (Drs Jacobs and Gøthgen and Ms Bozian), and the Departments of Neurology (Drs Jacobs and Gøthgen), Ophthalmology, and Physiology (Dr Jacobs), State University of New York, School of Medicine at Buffalo. Dr Karpik was a student at the State University of New York School of Medicine at the time of this study; she is now with Rush-Presbyterian-St Luke's Hospital, Chicago.

Reprint requests to Harry M. Dent Neurologic Institute, Millard Fillmore Hospital, 3 Gates Circle, Buffalo, NY 14209 (Dr Jacobs).



The inherent potential of the normal brain for "cross-talk" between the auditory and visual senses is demonstrated by rare, healthy individuals who sometimes see lights and colors when they hear certain sounds.¹⁻³ However, the occurrence of such auditory-visual synesthesias as a manifestation of disease of the CNS is not generally appreciated. We describe nine patients with visual loss due to lesions of the anterior portions of the visual pathways who experienced sound-induced photisms, and we present data suggesting that the effects of an acoustic startle reaction on a partially deafferent visual system may be important in the development of the phenomenon.

CLINICAL OBSERVATIONS

The cases are summarized in Table 1. The site of the lesion causing visual loss was the optic nerve in seven patients and the optic chiasm in two patients. A definite diagnosis was made in every patient except in case 9. Multiple sclerosis (MS) was diagnosed in three patients (cases 1 to 3) who had clear histories of exacerbations and remissions of disseminated neurologic deficits prior to the onset of visual symptoms associated with photisms. The patients with MS had unequivocally positive hot-bath tests⁴ and visual evoked responses (VERs) consistent with demyelination. Each had elevated serum total protein content, and two had elevations of γ -globulin fraction in the CSF. Each patient with MS improved with adrenocorticotropic hormone therapy. Tumors of the sella turcica-juxtassellar regions were diagnosed (by tomographic radiographs, angiography,

and computerized tomography [CT]) in cases 4 and 5. Craniotomy revealed a tuberculum sellae meningioma in case 5; the tumor type was unknown in patient 4, who refused surgery. Temporal arteritis was diagnosed in cases 6 and 7 by elevated ESRs and examination of temporal artery biopsy specimens. Patient 8 had been amaurotic on the right side for 25 years since surgery for removal of neurofibroma at the orbital apex. Probable vascular occlusive optic neuropathy was diagnosed in patient 9, a chronically hypertensive woman with atherosclerotic heart and peripheral arterial occlusive disease. Her cerebral angiogram revealed luminal narrowing and plaques of both cervical carotid arteries and right-sided intracavernous carotid stenosis. Fluorescein angiography revealed narrowed retinal arterioles, but no definite arteriolar occlusion. The onset of visual loss associated with photisms was sudden (seconds) in cases 8 and 9, over four to seven days in cases 1 to 3, 6, and 7, and gradual (six months and two years) in cases 4 and 5. The photisms were seen within one to three days after the first symptom of visual loss in eight patients, the only exception being patient 8, in whom photisms were first experienced three months after the onset of right-sided amaurosis. The first photism experienced by each patient was of the same degree of brightness as subsequent ones. There was no gradual "buildup" of photism intensity over time. Optic atrophy and Marcus Gunn pupillary reactions were present in the eye in which the photisms were seen in seven patients.

Photisms

The most commonly described photisms were small to large flashes of white light in the scotoma (Table 2). The sounds of walls "crackling" as they cooled at night, an

Table 1.—Clinical Features of Nine Patients*

Patient No./ Age, yr/Sex	Site	Disease	Field Defect	Visual Acuity	OA	Duration
1/25/F	Optic nerve	MS	Nasal, OS	OD 20/20 OS 20/70	+ OS	12 yr
2/38/F	Optic nerve	MS	Nasal, superior temporal, OD	OD 20/400-20/40 OS 20/20	+ OD	3 yr
3/26/M	Optic nerve	MS	Full-field scotoma, OD	OD LP OS 20/20	+ OD	18 mo
4/44/F	Chiasm	Tumor	Superior temporal, OD	OD 20/50 OS 20/20	+ OU	2 yr
5/52/F	Chiasm	Tumor	Bilateral constriction	OD 20/30 OS 20/30	—	2 yr
6/61/F	Optic nerve	Arteritis	Full-field scotoma OD	OD 20/800 OS 20/40	+ OD	11 mo
7/49/M	Optic nerve	Arteritis	Full-field scotoma, OD	OD LP-20/25 OS 20/20	—	5 mo
8/71/M	Optic nerve	Postsurgical	Amaurosis, OD	OD NLP OS 20/20	+ OD	25 yr
9/70/F	Optic nerve	Vascular occlusive(?)	Superior altitudinal nasal scotoma, OD	OD 20/50 OS 20/30	+ OD	18 mo

*OA indicates optic atrophy; MS, multiple sclerosis; LP, light perception only; NLP, no light perception; +, present; —, absent.

Table 2.—Characteristics of Photisms and Sounds That Induced Them

Patient No.	Photism Appearance	Color	Location	Sounds
1	Flame, flashbulb	Red-orange-white, white	In scotoma	Not sure (sharp)
2	Spray, microscope light, kaleidoscope, spot, pollywogs	White, pink, red, black, green	In and out of scotoma	Clap, computerized tomography gantry
3	Flash	White-yellow	In scotoma	Walls crackling, digital clock, pencil striking desk, television scintillating and crackling
4	Light bulb	White-blue	In scotoma	Not sure (soft)
5	Flash	White	In and out of scotoma	Car or motorcycle engines, others (loud)
6	Flashbulb	White	In scotoma	Electric blanket, digital clock
7	Petal, ameba, goldfish	Pink, white, yellow	In and out of scotoma	Furnace, dog bark, tray crash, voices
8	Plaid	Green	In scotoma	Book or fist slamming desk, others (loud)
9	Flashbulb	Pink	In and out of scotoma	Furnace, door slam, television, radio, voices

extinguished television set "scintillating, crackling" as it cooled, a digital clock changing numbers, and a pencil striking a desk induced a large, round flash of light with peripheral radiations in the upper portion of the scotoma of patient 3 (Fig 1). Soft sounds (not further identifiable) perceived as coming from the right by patient 4 induced an oval "light bulb" of bright white light surrounded by a pale blue rim in the upper peripheral portion of her right superior quadrant achromatopsia. Rarely, the flash of light was homogeneously colored as in patient 9, in whom the sounds of a gas furnace turning on, a door slamming, or voices induced a solid pink photism that

filled the entire visual field (scotomatous and nonscotomatous portions) of the right eye.

Other photisms were more complex. An illuminated white, yellow, orange, and red flame photism filled the nasal scotoma of patient 1 when she heard "sharp" noises to her left (Fig 2). On other occasions, similar sharp sounds induced a plain white flashbulb hallucination in an identical location. The sounds of a furnace turning on ("muffled"), a dog bark, a tray crashing to the floor, and a woman's voice on the right induced an "explosive" central brightness followed instantaneously by oscillating pink lines moving from central to peripher-

al ("petal" effect) to fill the scotomatous right eye of patient 7 (Fig 3, left and center). On other occasions, a centrally located pink strip likened to an ameba was produced by the same sounds (Fig 3, right). Rarely, a bright yellow-gold photism shaped like a goldfish appeared in the inferior field of the right eye in response to the same sounds perceived as coming from the right. A "spray" photism of numerous tiny, round, bright dots filled the entire field (scotomatous and nonscotomatous portions) of the right eye when patient 2 heard the clap of hands or the "thud-like" sounds of a moving CT gantry (Fig 4). A small round light ("microscope") containing irregular dark "hairs" appeared in the inferior portion of the field, and a "whirling kaleidoscope" of pink dots moving centrally to peripherally to fill the field of the right eye appeared when the same sounds were heard on other occasions. Each patient's photisms lasted "a split second, an instant."

Five patients (cases 3, 5, 6, 8, and 9) experienced a single stereotyped photism (always the same in appearance and location); patients 1 and 4 experienced two; and patients 2 and 7 experienced three to five different photisms.

Sounds

The different provoking sounds that could be identified (Table 2) ranged from two (cases 2, 5, and 8) to five (cases 3 and 9). They fell into five categories as follows: (1) soft clicks (eg, electric-blanket thermostat); (2) thuds that were of soft (eg, digital clock), medium (eg, CT gantry, pencil striking desk), or loud intensities (eg, door, fist, book slam); (3) soft cracklings (eg, walls and television cooling); (4) loud, harsh (eg, dog bark, tray crash, engine roar); and (5) voices that were of soft or medium intensities (eg, nurse speaking, voices from television or radio) or loud (hospital paging system). All of the provoking sounds seemed to be of mixed frequencies of wide range (door slam, 250 to 1,500 Hz; digital




Fig 1.—Case 3. Top, Large, irregularly bordered right central scotoma (motion) partially surrounded a chromatopsic periphery where light and motion could be perceived. Visual field of left eye (not shown) was normal. Bottom, "Flash" photism.

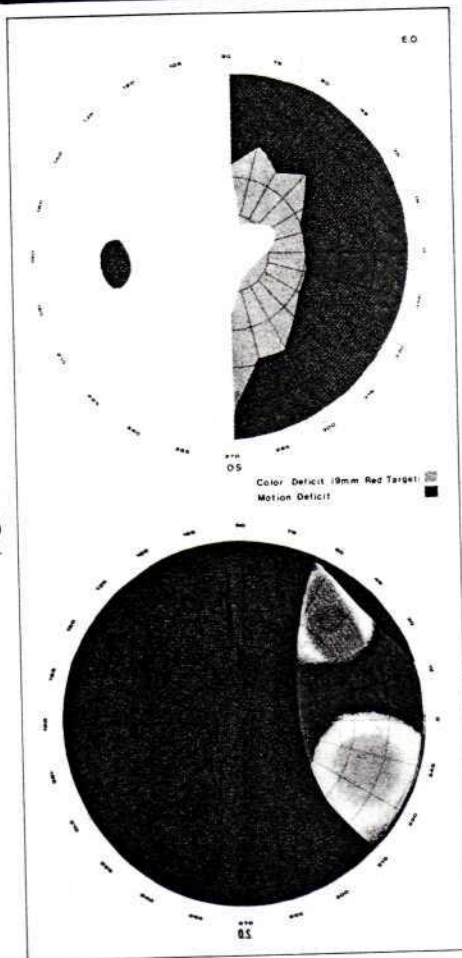


Fig 2.—Case 1. Top, Macula sparing nasal defect of left visual field. Visual field of right eye (not shown) was normal. Bottom, "Flame" photism induced by "sharp" sounds.

Fig 3.—Case 7. Left, Defect of right visual field including nasal crescentic anopsia, nasocentral achromatopsia, and temporal dyschromatopsia. Visual field of left eye (not shown) was normal. Center, "Petal" photism. Right, "Ameba" photism.

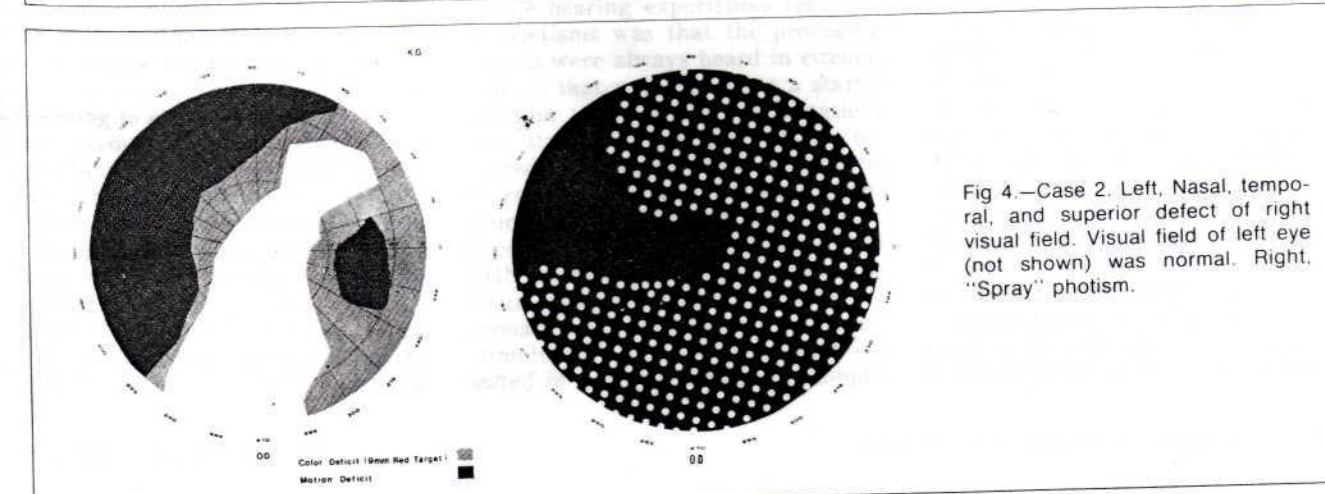
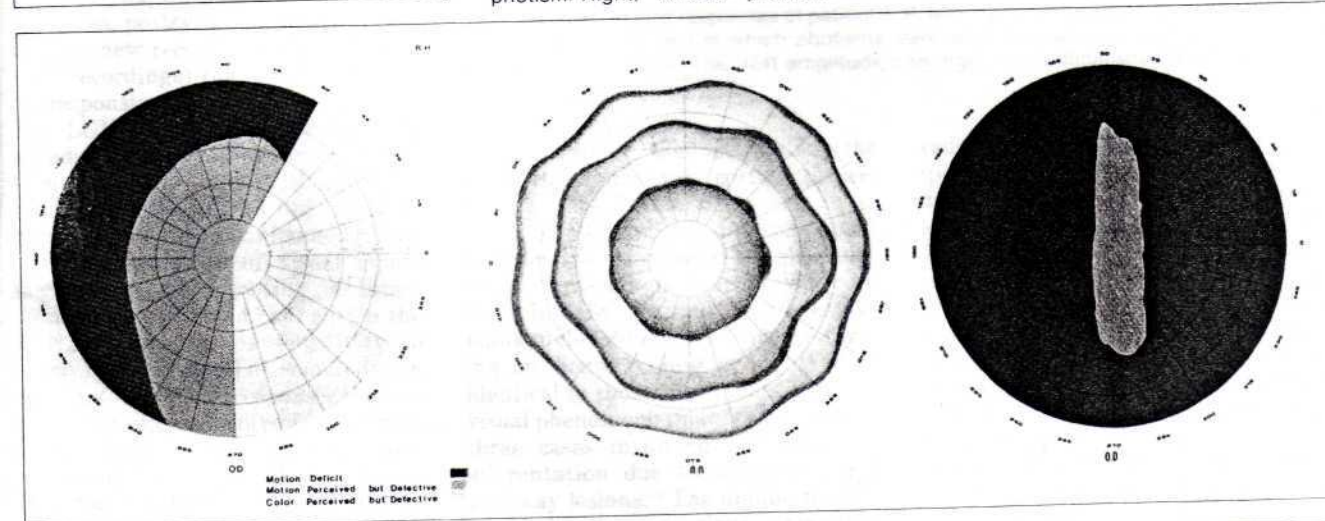


Fig 4.—Case 2. Left, Nasal, temporal, and superior defect of right visual field. Visual field of left eye (not shown) was normal. Right, "Spray" photism.

clock, walls or television crackling, 500 to 2,000 Hz; dog bark or tray crash, 1,000 to 2,000 Hz; voices, 1,000 to 3,000 Hz). Two patients who could not identify any of the provoking sounds described them as sharp (case 1) or soft (case 4). Patients 5 and 8, who could identify some but not all of the provoking sounds, described those that they could not identify as loud.

The sounds inducing the photisms were always reported as being heard from the side ipsilateral to the eye in which the photism was seen. The click of an electric blanket thermostat induced a flashbulb photism in the right eye of patient 6 only when the thermostat located to her right clicked; the same clicking from her husband's thermostat located to her left never induced the phenomenon. A petal photism was perceived as coming from the right eye of patient 7 when a nurse spoke into his right ear. The photism never occurred when the nurse spoke into his left ear. The frequencies with which the photisms occurred was from one to ten times per night for between 1.5 and 11 months in five patients (cases 1, 2, 5 to 7), two times per week for 18 months in one patient (case 3), five times during 18 months (approximately once every three to four weeks) changing to two to three per day during the next six months for patient 4, and three times per year for 25 years for patient 8. The photisms disappeared in patient 7 after five months but have persisted in the other patients. In patients who saw more than one photism, the same sound that induced a given photism on one occasion might induce a different one on another occasion. The sound of a moving CT gantry might induce a spray photism in the right eye of patient 2 on one occasion and a microscope light photism on another occasion. In all patients, a given sound might induce a photism on one occasion but fail to do so on numerous other occasions.

Circumstances of the Photisms and Associated Phenomena

The conditions in which the photisms occurred were similar in seven patients (cases 1 to 3, 5 to 7, and 9). They were always relaxed, drowsy, or dozing in a quiet, dark or dimly illuminated room with their eyes closed. The photisms occurred between the time they entered the dark and fell asleep; this period never exceeded one hour. Photisms were not experienced when they awakened later in the night. Patients 4 and 8 differed from the others in that they experienced photisms in the light (bright daylight, fluorescent or standard room lighting) with their eyelids opened and never experienced them in the dark. Patient 4 was relaxed (but not drowsy) and patient 8 was "tense, anxious, concentrating" when sounds induced the photisms.

Each patient was startled when the photism occurred. Frequently, the startle was associated with a gross body jerk that resulted in arousal from early sleep or drowsiness. Patient 8 was certain that the sound had startled him. The others were uncertain as to whether the sound or the

photism had startled them. Each patient stated that the sound, the photism, and the startle seemed to occur simultaneously. Patients 1, 2, 4, and 9 described the experience as "seeing the sound on the inside of their eyelids."

Patients 1, 2, 4, and 7 saw spontaneous (not sound-induced) photisms in the involved eye as well as those induced by sound. Patient 7 began experiencing spontaneous photisms at a time when vision in the right eye had improved to near normal and sound-induced photisms were ceasing. They continued for one month after sound-induced photisms had ceased completely. In cases 1, 2, and 4, spontaneous photisms began at approximately the same time as those induced by sounds and have continued (approximately 20% as frequently as those induced by sound). Spontaneous photisms occurred under identical conditions and were of similar characteristics as those induced by sound. When spontaneous photisms occurred, they were not related to eye movement, sudden lid closure, or any other identifiable maneuver. Photisms could not be induced by tapping or application of a vibrating tuning fork to the orbital bone or globe (lids closed) or vigorous deviations of the eyes.

Neurophysiologic Studies

Visual evoked responses (black-white checkerboard reversals) and auditory evoked responses (AERs; binaural and monaural stimuli, broad band clicks), using standard methods¹⁻¹⁰ (Nicolet, 1170 averager), were performed on patients 1, 2, and 5 to 9. All seven patients had normal AERs but abnormal VERs (bilateral, case 1, unilateral, others). The mean latency to P₂ (second positive deflection on derived EEG after stimulus onset) was 140.2 ms (120.8 to 170.4 ms) in the eye in which the photism was seen and 108.4 ms (101.9 to 129.5 ms) in the opposite eye (Fig 5). The range of normal P₂ latencies for our laboratory is 95 to 110 ms. The VER amplitudes from the involved eyes were reduced to 50% to 60% of normal.

Photism induction was attempted in cases 1 to 3, 6, 7, and 9. Tones of 200 ms at frequencies of 250, 500, 1,000, 1,500, 2,000, and 3,000 Hz were presented monaurally through earphones at intensities of 60, 70, 80, 85, and 95 dB, sound pressure level (SPL) to each patient immediately, after five minutes, and then at successive ten-minute intervals after they had entered a pitch-black (but not soundproofed) laboratory. Patient 2 saw an irregularly edged spot (green center, pink rim) in the inferior field of the right eye when a 2,000-Hz tone at 95 dB, SPL was delivered to the right ear. The photism was induced on five separate occasions by that tone (but none of the others tested) between 40 and 47 minutes in the dark but could not be induced prior to 40 minutes or after 47 minutes. Patient 7 experienced the pink ameba photism (Fig 3, right) in his right eye on two occasions (40 to 43 minutes in the dark) with a 1,000-Hz tone at 90 dB SPL delivered to his right ear. After 20 minutes in the dark, he experienced the petal photism (Fig 3, cen-

ter) when he heard a woman's voice over the hospital paging system, but attempts to induce photisms through the earphones at that time (ie, approximately 20 minutes) were unsuccessful. No photisms were induced by tones delivered to the left ear of either patient. The sound of a pencil striking a desk surface induced a flash photism (Fig 1) in the right eye of patient 3 after 90 minutes in the dark. However, no photisms could be induced by various tones delivered through earphones. Photisms that occurred in the experimental setting were experienced with eyelids closed and, as best as the patients could tell, were not related to eye movement, but eye movements were not electronically monitored. No photisms occurred during the experiment in cases 1, 6, or 9.

COMMENT

These cases illustrate an interaction between the auditory and visual systems that may become manifest in some diseases of the anterior visual pathways. The photisms always occurred within scotomas (exclusively, five patients; inside and outside scotomas, four patients), constituting a form of positive visual phenomenon resulting from intermodal stimulation.¹¹

The VERs revealed that visual deafferentation was incomplete in each patient tested, including patient 8, who had been subjectively blind in the right eye (in which photisms were seen) for 25 years. The VERs elicited on stimulation of the scotomatous eyes revealed conductive delays (prolonged P₂ latencies) and reduced evoked potential amplitudes. Unilateral VER abnormalities (six of seven patients tested) were always observed on stimulation of the eye in which photisms were seen. Bilateral VER abnormalities observed in case 1 are accounted for by an episode of right-sided retrobulbar neuritis four years before the onset of left papillitis associated with photisms. The VER pattern recorded in these patients has most often (although not exclusively) been associated with demyelination of the visual system,¹² which would be expected in our three patients with MS and which may be a component of pathologic changes in the compressive and ischemic diseases of the other six patients. The possible relevance of demyelination to the development of the phenomenon is also suggested by another report of nine patients with optic neuritis due to MS who experienced hallucinations of light with eye movement.¹³ Regardless of specific etiology, the propensity of the partially deafferent, defectively conducting visual system to produce photisms is evidenced by the fact that four of our

patients (three with the demonstrated VER abnormality) experienced spontaneous as well as sound-induced photisms.

Each patient had evidence of a lesion involving the presynaptic portions of the third-order neuron (axons of retinal ganglion cells) of the visual pathway. Partial deafferentation at this site might produce a heightened state of excitation of the fourth-order neuron (lateral geniculate nucleus [LGN]) since impulse and chemical trophic influences from the third-order neuron on the LGN would still be partially intact (albeit reduced). The LGN supersensitivity might particularly be expected in purely or predominantly demyelinating lesions with axons left intact. Supersensitive states of postjunctional elements following partial deafferentation have been demonstrated in the autonomic and peripheral nervous systems and the CNS (including visual).¹⁴⁻¹⁸ Partial rather than complete deafferentation has been stressed as the necessary element for the development of such postjunctional supersensitivity.¹⁶⁻¹⁹ The anatomic basis of the supersensitivity may be sprouting of preserved elements, which has been observed in many instances of partially deafferent postsynaptic elements.¹⁶⁻²⁶ In such instances, postsynaptic elements may develop new receptive fields (intracellular recordings) that are heightened in responsiveness to novel inputs.¹⁹ The LGN is normally responsive to sounds as well as visual stimuli. Sound stimuli elicit transient discharges that can be recorded from the LGN of normal experimental animals.²⁷⁻³⁰ Partial deafferentation of visual inputs might result in sprouting of intact sound-responsive elements within the LGN, heightening its sensitivity to sound to the point that sounds begin inducing threshold responses for vision, resulting in photisms. The retinotopic map is near-perfectly preserved in the LGN (likened to an "internal retina").^{28,31,32} Partially deafferent retinal axons corresponding to the scotoma plotted by perimetry would be the most sensitive components (lowest thresholds for responding to sound) of the LGN, which may account for the occurrence of sound-induced photisms within scotomas. The colliculus superior (another fourth-order neuron for vision) might also become supersensitive in the state of partial deafferentation described. This nucleus is also normally responsive to sounds and has retinotopic organization, but its role in the genesis of sound-induced photisms

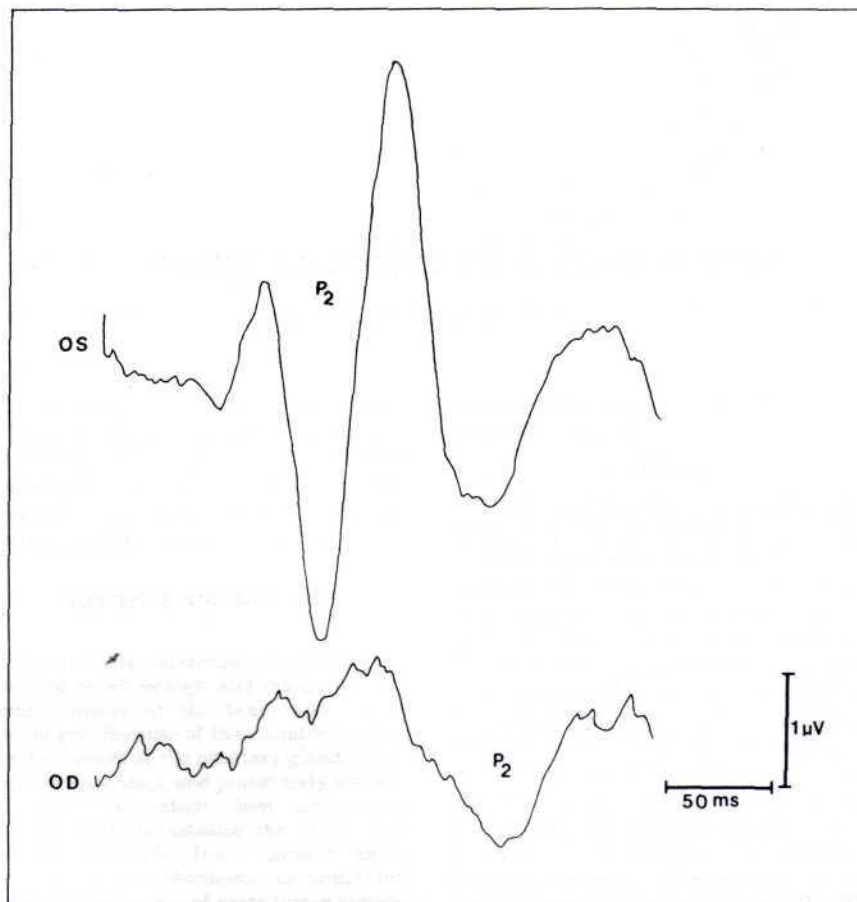


Fig 5.—Visual evoked responses of patient 9; P₂ latency is prolonged (170.4 ms) following stimulation of right eye in which photisms were seen, but normal (104.1 ms) following stimulation of left eye. The VER amplitude from right eye is diminished due to patient's right scotoma.

seems unlikely because, unlike the LGN, it has no direct cortical projections in the primate.^{31,32}

There was nothing unusual about the sounds that induced the photisms; most were sounds that are encountered in daily life, and some (electric-blanket click, dog bark, furnace turning on, house cooling at night) were identical to those that induced similar visual phenomena in another report of three cases involving unilateral deafferentation due to anterior visual pathway lesions.³³ The unique feature of the hearing experiences resulting in photisms was that the provoking sounds were always heard in circumstances that would promote a startle reaction to sound, and each patient was startled when the photism occurred. The startle reaction may be extremely important in the genesis of sound-induced photisms, since it produces a sudden, brief discharge in the LGN as well as other portions of the visual system that are normally responsive to sound as well as visual stimuli.³⁴⁻³⁹ Visual deafferentation resulted in dramatic increase in ampli-

tudes and fields of these discharges (pontogeniculo-occipital spikes) induced by startling sounds in monkeys.⁴⁰ The exaggerated startling effect on an already supersensitive LGN may be the critical element resulting in a threshold discharge for vision on a sound stimulus that produces photisms. The briefness of the sound-induced photisms and their tendency to habituate (subjectively reported by all patients, experimentally demonstrated in cases 2 and 7) are features that the phenomenon shares with the startle reaction to sound.^{35,37,38}

The startle reaction also results in abrupt eyelid blinking and deviation of the eyes toward the offending sound, both of which might induce photisms. However, we were unable to induce photisms by forced blinking, eyelid closures, globe-orbit tapping, or eye movement at any time, including the period when photisms were being induced experimentally by sounds delivered through earphones.

The requirement for the sound to be heard by the ear ipsilateral to the eye in which photisms were seen (subjec-

tively reported by all patients, experimentally demonstrated in cases 2 and 6) cannot be adequately explained. Responsiveness to auditory stimuli from either side would be expected because nasal retinal fibers from one eye (involved in scotomas of seven patients) are represented in the contralateral LGN, and auditory inputs are bilaterally represented in the brainstem reticular formation.

The physiologic basis of sound-induced photisms experienced in other pathologic states (eg, congenitally blind, drug intoxication) may be entirely different from that sug-

gested for unilateral partial deafferentation of the anterior visual pathway. The numerous regions of the brain where visual and auditory pathways lay in close anatomic proximity and on which postsynaptic fibers from the two systems converge might serve as substrates for the synesthesia in those cases.³³

Sound-induced photisms do not appear to be unusually rare in patients with lesions of the anterior visual pathways. The phenomenon was experienced by the last seven of 20 patients with optic nerve lesions and two of nine patients with optic chiasm

lesions whom we have examined. However, such patients must be specifically questioned about the symptom because, like patients with certain other forms of auditory and visual positive phenomena,⁴⁰⁻⁴³ they often do not spontaneously report the symptom.

This research was supported by grants from the Delaware North Corporation and the Harry M. Dent Family Foundation, Buffalo, NY.

Werner Noell, MD, PhD, of the State University of New York at Buffalo, reviewed the manuscript and provided valuable constructive criticism.

References

- Colman WS: Further remarks on 'colour hearing.' *Lancet* 1898;1:22-24.
- Ortman O: Theories of synesthesia in the light of a case of color-hearing. *Hum Biol* 1933;5:155-211.
- Dudycha GJ, Dudycha MM: A case of synesthesia: Visual-pain and visual-audition. *J Abnorm Soc Psychol* 1935;30:57-69.
- Duke-Elder S, Scott GI: *Neuro-ophthalmology*, vol 12, in Duke-Elder S (ed): *System of Ophthalmology*. St Louis, CV Mosby Co, 1971, pp 571-573.
- Critchley M: Ecstatic and synaesthetic experiences during musical perception, in Critchley M, Henson RA (eds): *Music and the Brain*. Springfield, Ill, Charles C Thomas Publisher, 1977, pp 217-232.
- Davis FA: The hot bath test in the diagnosis of multiple sclerosis, in Bender MB, Feldman M (eds): *The Approach to Diagnosis in Modern Neurology*. New York, Grune & Stratton Inc, 1967, pp 80-82.
- Starr A, Anchor LJ: Auditory brain stem responses in neurological disease. *Arch Neurol* 1975;32:761-768.
- Operating Manual for Ca-1000 Clinical Averager System in Audiometry and Neurological Applications*. Madison, Wis, Nicolet Instrument Corp, 1977.
- Operating Manual for Ca-1000 Clinical Averager System in Visual Evoked Response Application*. Madison, Wis, Nicolet Instrument Corp, 1978.
- Halliday AM, McDonald WI, Muskin J: Visual evoked response in multiple sclerosis. *Br Med J* 1973;4:661-664.
- Taylor J (ed): *Selected Writings of John Hughlings Jackson*. New York, Basic Books Inc, 1958, vol 2, pp 16-27.
- Halliday AM, McDonald WI, Muskin J: Visual evoked potentials in patients with demyelinating disease, in Desmedt JE (ed): *Visual Evoked Potentials in Man: New Developments*. Oxford, England, Clarendon Press, 1977, pp 438-449.
- Davis FA, Bergen D, Schauf C, et al: Movement phosphenes in optic neuritis: A new clinical sign. *Neurology* 1976;26:1100-1104.
- Echlin FA, McDonald J: The supersensitivity of chronically isolated and partially isolated cerebral cortex as a mechanism in focal cortical epilepsy. *Trans Am Neurol Assoc* 1954;79:75-79.
- Burke W, Haylow WR: Disuse in the lateral geniculate nucleus of the cat. *J Physiol* 1968;194:495-519.
- Sharpless SK: Isolated and deafferented neurons: Disuse supersensitivity, in Jasper HH, Ward AA, Pope A (eds): *Basic Mechanisms of the Epilepsies*. Boston, Little Brown & Co, 1969, pp 329-348.
- Ward AA: The epileptic neuron: Chronic foci in animals and man, in Jasper HH, Ward AA, Pope A (eds): *Basic Mechanisms of the Epilepsies*. Boston, Little Brown & Co, 1969, pp 263-288.
- Roper S, Ko CP: Synaptic remodeling in the partially denervated ganglion in the heart of the frog, in Cotman CW (ed): *Neuronal Plasticity*. New York, Raven Press, 1978, pp 1-23.
- Merrill EG, Wall PD: Plasticity of connection in the adult nervous system, in Cotman CW (ed): *Neuronal Plasticity*. New York, Raven Press, 1978, pp 97-111.
- Stavarsky G: *Supersensitivity Following Lesions of the Nervous System*. Toronto, University of Toronto Press, 1961.
- Weisel TN, Hubel DH: Single cell responses in the striate cortex of kittens deprived of vision in one eye. *J Neurophysiol* 1963;26:1003-1017.
- Liu CN, Chambers WW: Intrasprouting of dorsal root axons: Development of new collaterals and preterminals following partial denervation of the spinal cord in the cat. *Arch Neurol* 1958;79:46-61.
- Cunningham TJ: Sprouting of the optic projections after cortical lesions. *Anat Rec* 1972;172:298.
- Goodman DG, Horel JA: Sprouting of the optic tract projections in the brain stem of the rat. *J Comp Neurol* 1966;127:71-83.
- Nakamura Y, Mizunn N, Koneski A: Synaptic reorganization of the red nucleus after chronic deafferentation from cerebellorubral fibers. *Brain Res* 1974;82:293-301.
- Edds MV Jr: Collateral nerve regeneration. *Q Rev Biol* 1953;28:260-276.
- Arden GB, Soderberg U: The relationship of lateral geniculate activity to the electrocorticogram in the presence or absence of the optic tract input. *Experientia* 1959;15:163-164.
- Duke-Elder S, Weale RA: *The Physiology of the Eye and of Vision*, vol 4, in Duke-Elder S (ed): *System of Ophthalmology*. St Louis, CV Mosby Co, 1968, pp 516-534.
- Cohen B, Feldman M: Relationship of electrical activity in pontine reticular formation and lateral geniculate body to rapid eye movements. *J Neurophysiol* 1968;31:806-817.
- Feldman M, Cohen B: Electrical activity in the lateral geniculate body of the alert monkey associated with eye movements. *J Neurophysiol* 1968;31:455-466.
- Singer W: Control of thalamic transmission by corticofugal and ascending reticular pathways in the visual system. *Physiol Rev* 1977;57:386-420.
- Duke-Elder S, Wybar KC: *The Anatomy of the Visual System*, vol 2, in Duke-Elder S (ed): *System of Ophthalmology*. St Louis, CV Mosby Co, 1968, pp 698-701.
- Lassell S, Cohen MM: Phosphenes induced by sound. *Neurology* 1979;29:1524-1527.
- Bizzi E, Brooks DC: Functional connections between pontine reticular formation and lateral geniculate nucleus during sleep. *Arch Ital Biol* 1963;101:666-680.
- Gogan P: The startle and orienting reactions in man: A study of their characteristics and habituation. *Brain Res* 1970;18:117-135.
- Sem-Jacobsen CW: Sudden alarming noise effect on brain functions and EEG changes. *Acta Otorhinolaryngol Belg* 1971;25:218-220.
- Groves PM, Wilson CH, Boyle RD: Brainstem pathways, cortical modulation, and habituation of the acoustic startle response. *Behav Biol* 1974;10:391-418.
- Bowker RM, Morrison AR: The startle reflex and PGO spikes. *Brain Res* 1976;102:185-190.
- Feldman M, Cohen B: Eye movement responses in the calcarine cortex after retinal ablation. *Physiologist* 1967;10:168.
- Bender MB, Feldman M, Sobin AJ: Palinopsia. *Brain* 1968;91:321-338.
- Jacobs L, Feldman M, Bender MB: Palinacousis or persistent auditory sensations. *Trans Am Neurol Assoc* 1971;96:123-126.
- Jacobs L, Feldman M, Bender MB: The persistence of visual and auditory percepts as symptoms of irritative lesions of the cerebrum of man. *Z Neurol* 1972;201-8.
- Jacobs L, Feldman M, Diamond SP, et al: Palinacousis: Persistent or recurring auditory sensations. *Cortex* 1973;9:275-287.